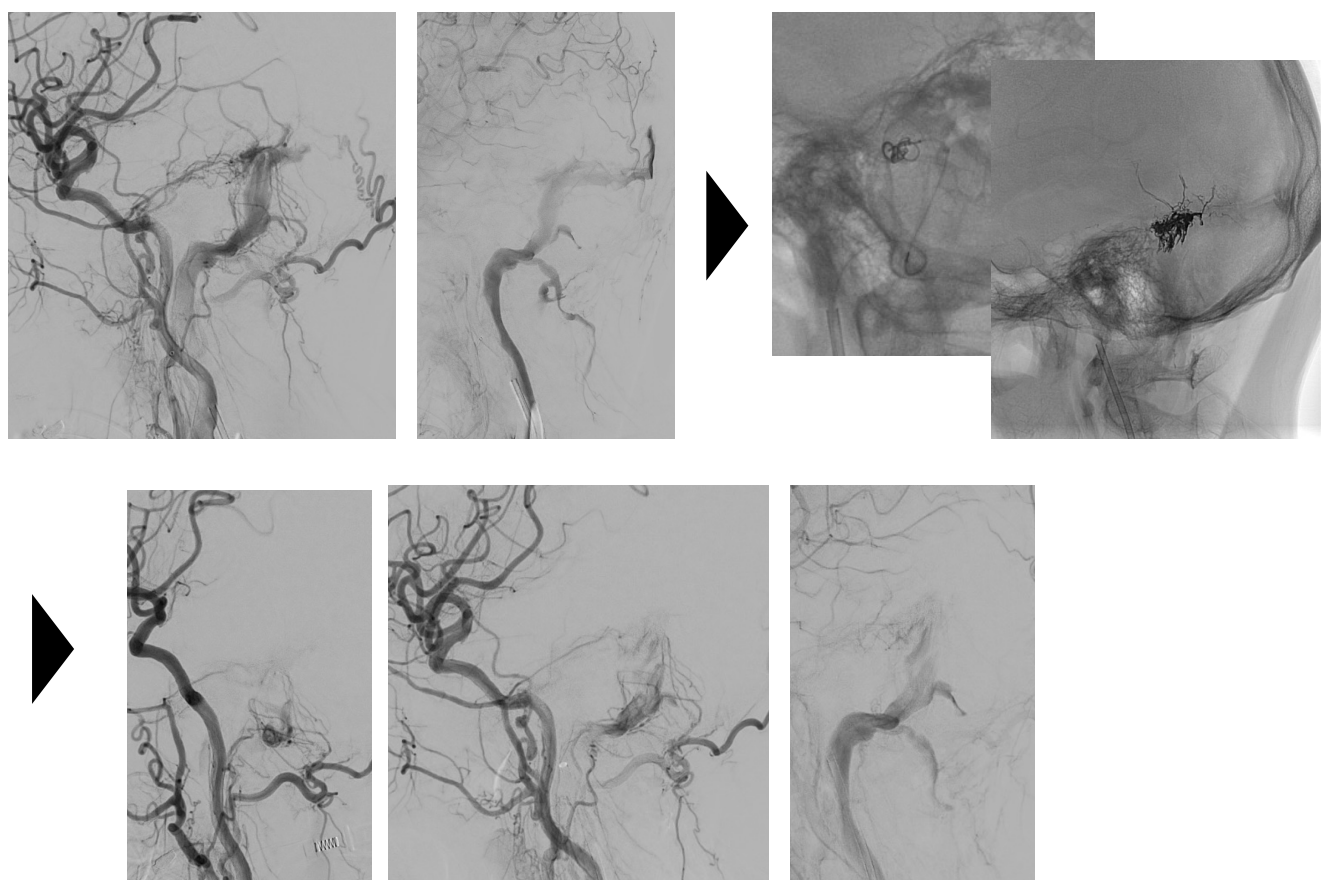
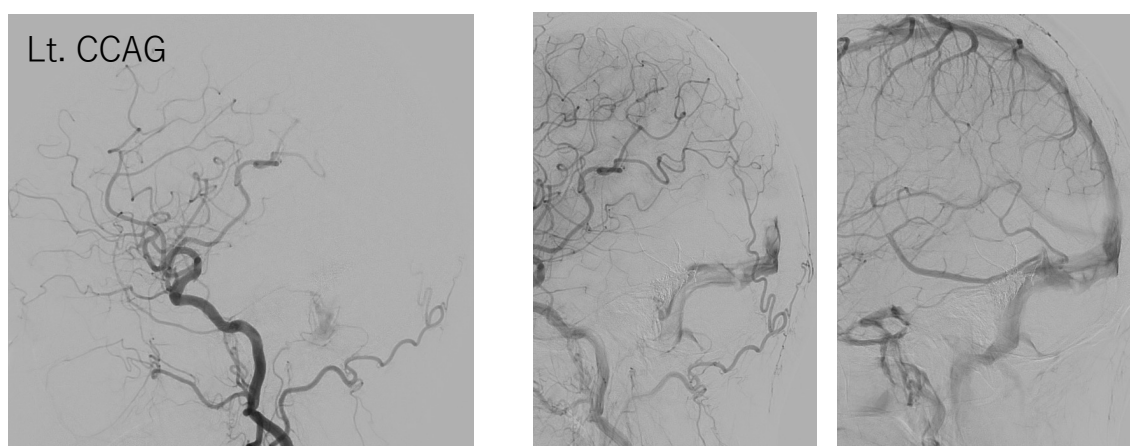


Case KCGH-4	72歳、女性 72y, Female
病名 Diagnosis	S状静脈洞部硬膜動静脈瘻治療後増悪 Aggravation of sigmoid sinus dural arteriovenous fistula
現病歴 History	2022年1月頃から左耳鳴出現。左S状静脈洞部の硬膜動静脈瘻に対して2022年10月にpara sinusに対してコイル塞栓、左MMAよりOnyxTAE施行し、Borden type 1となった。治療後半年のDSAで横静脈洞への逆流を認めた。 We treated the patient who had been experiencing left ear tinnitus since January 2022. On October 2022, coil embolization was performed on the para sinus, followed by Onyx TAE from Lt. MMA. After the treatment, the condition changed to Borden type I. DSA performed after six months showed retrograde flow into the transverse sinus.
既往歴 Past history	左室肥大 Left ventricle atrophy
内服歴/家族歴 Medication/family history	特記無し No medication/no family history

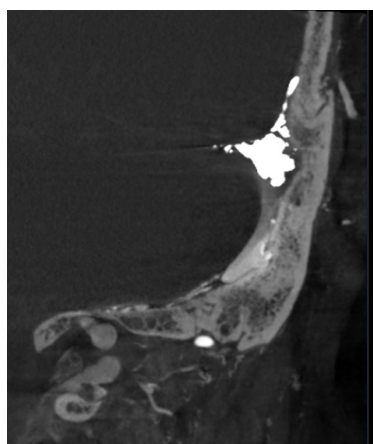
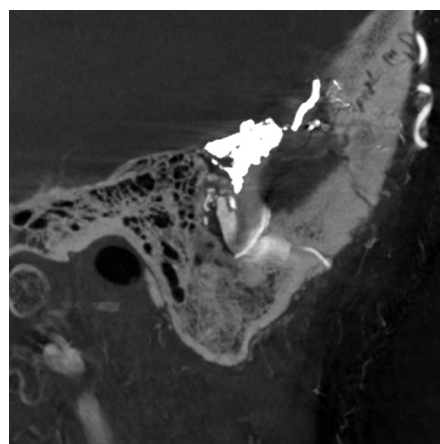
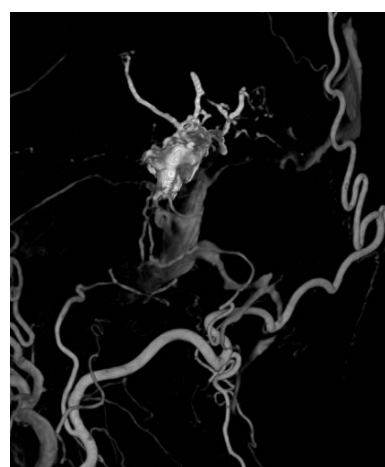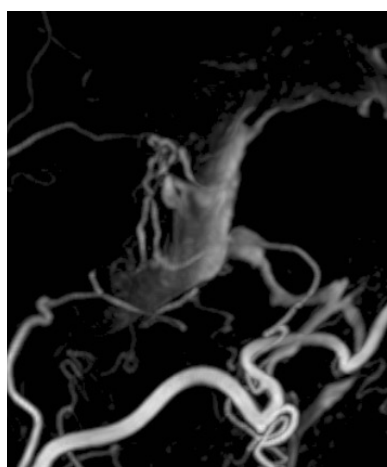
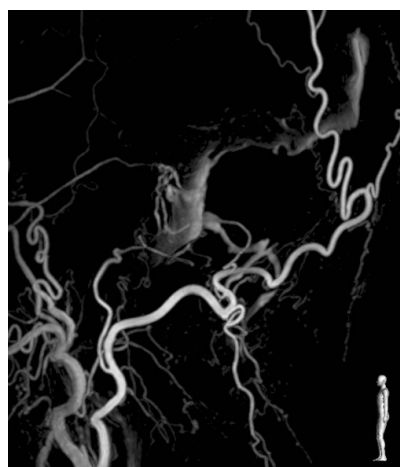
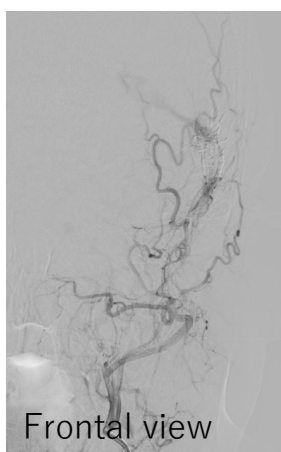
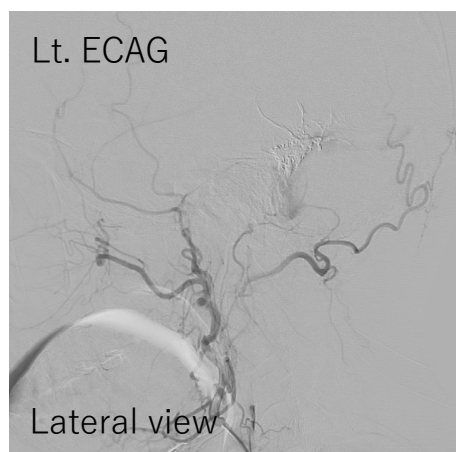
Previous treatment



After 6 months



Case KCGH-4	72歳、女性 72y, female
病名	S状静脈洞部硬膜動静脈瘻治療後増悪
Diagnosis	Aggravation of sigmoid sinus dural arteriovenous fistula



Feeder
 Lt. MMA petrosquamous br.
 OA mastoid br.
 OA stylomastoid br.

CVR (-)

Borden type I
 Cognard type IIa

