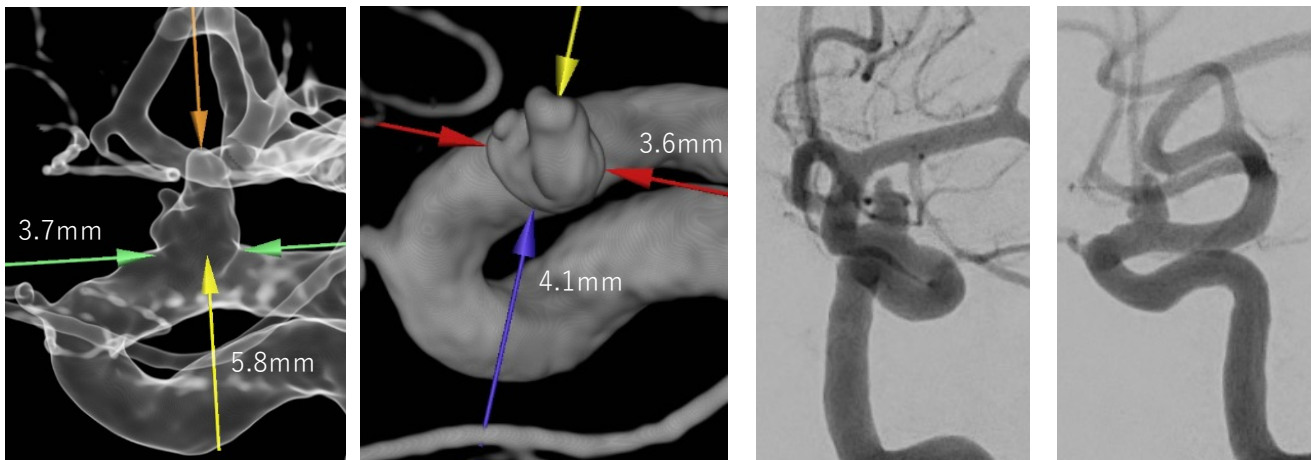
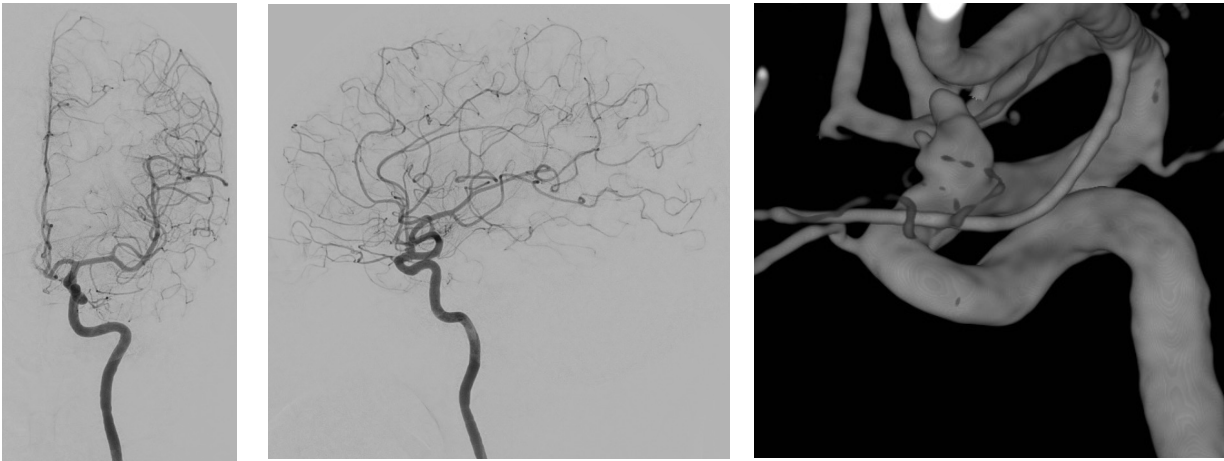

Case KCGH-5	52歳、女性 52y, Female
病名 Diagnosis	左内頸動脈傍鞍部動脈瘤 Lt. ICA paraclinoid aneurysm
現病歴 History	頭部MRAで左内頸動脈傍鞍部に動脈瘤を指摘された。 Lt. ICA aneurysm was incidentally detected by MRA
既往歴 Past History	片頭痛 Migraine
内服薬 Medication	ASA100、CLP75 (14日前から開始) Aspirin 100mg and Clopidogrel 75mg was started 14 days prior to procedure
家族歴 Family History	くも膜下出血の家族歴なし。父が未破裂脳動脈瘤疑いあり。 No family history of SAH. Her father was suspected of aneurysm



Lt. ICA paraclinoid aneurysm
neck: 3.7mm height 5.8mm, dome 4.1*3.6mm

