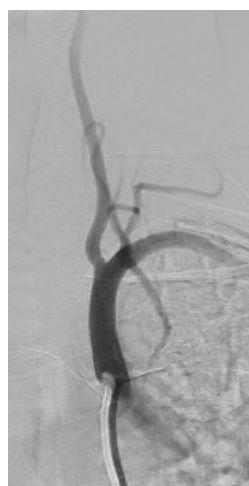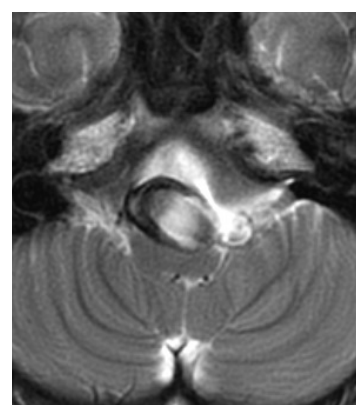
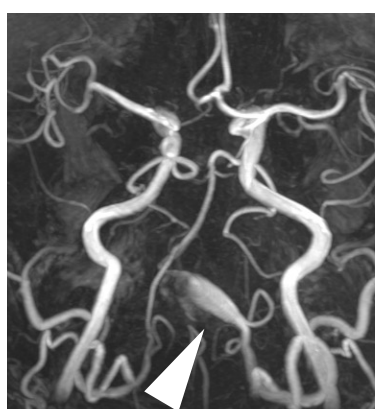
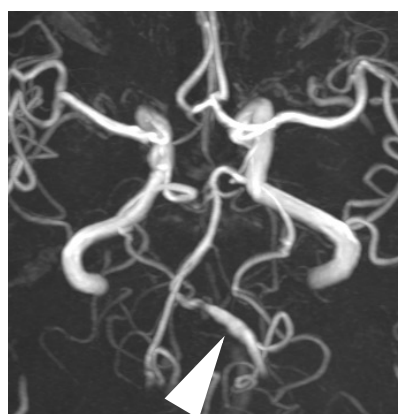
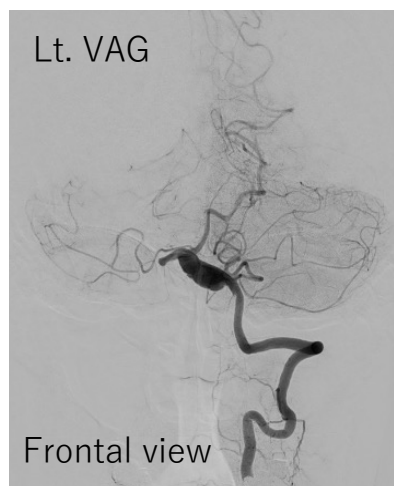


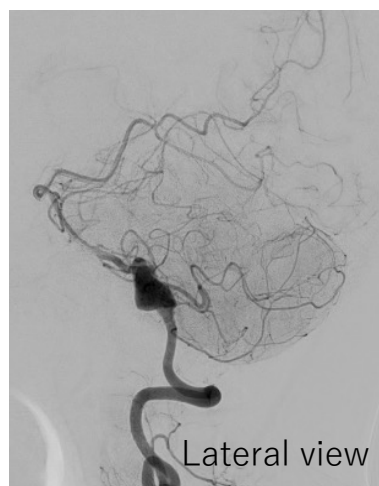
Case KCGH-6	52歳、女性 52y, Female
病名 Diagnosis	左椎骨動脈解離性動脈瘤（部分血栓化） Lt. VA dissecting aneurysm (partially thrombosed)
現病歴 History	頭痛の精査で施行されたMRIで左椎骨動脈瘤を指摘された。経過観察となっていたが、徐々に増大、部分血栓化を認めた。 Lt. VA dissecting aneurysm was detected by MRI for examination of headache. The patient was under observation, but the aneurysm gradually enlarged and partial thrombosis was observed.
既往歴 Past History	乳がん、甲状腺癌、子宮筋腫 breast cancer, thyroid cancer, uterine fibroids
内服薬 Medication	バイスピリン100mg、クロピドグレル 75mg(14日前から) Aspirin 100mg and Clopidogrel 75mg started 14days prior to procedure
家族歴 Family History	くも膜下出血および未破裂動脈瘤の家族歴なし No family history of SAH/aneurysm



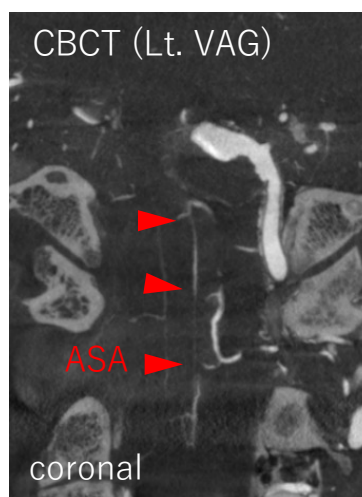
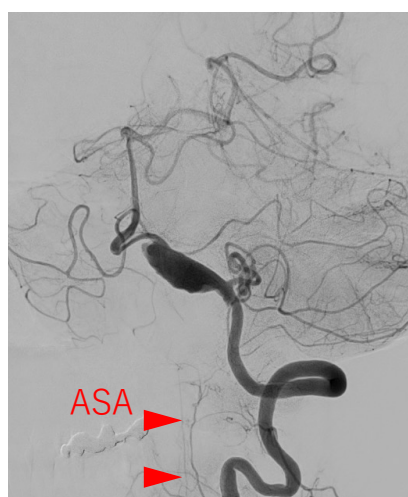
Lt. VAG



Frontal view

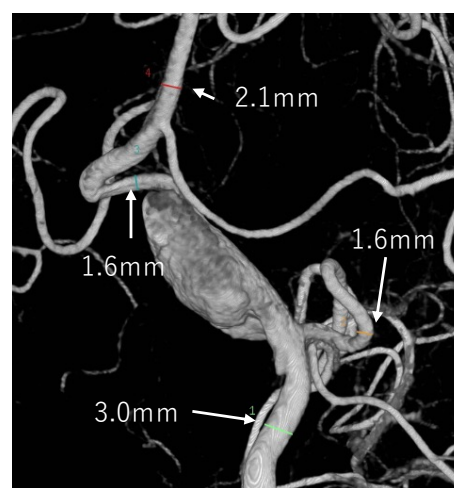


Lateral view



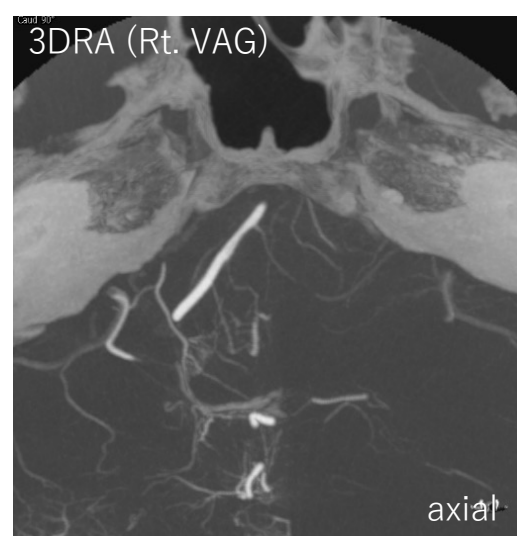
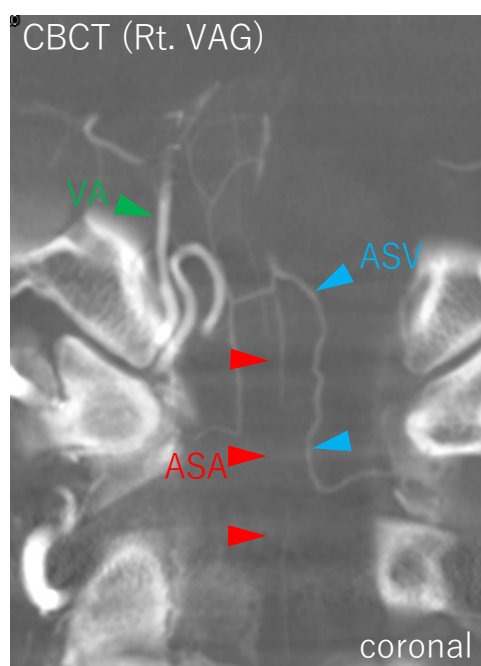
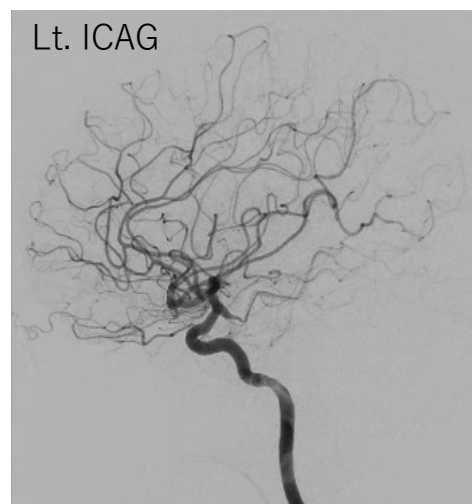
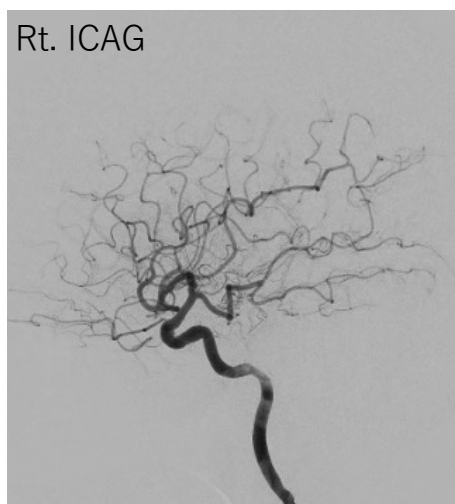
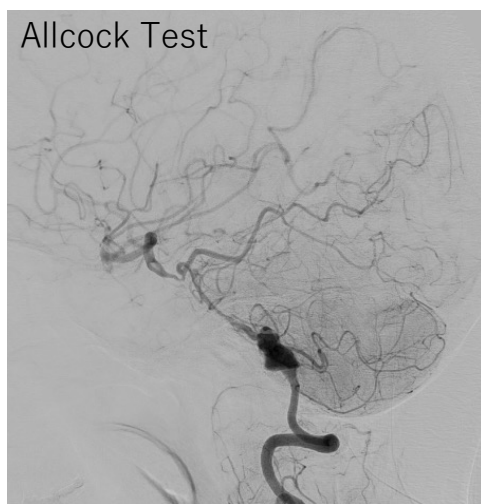
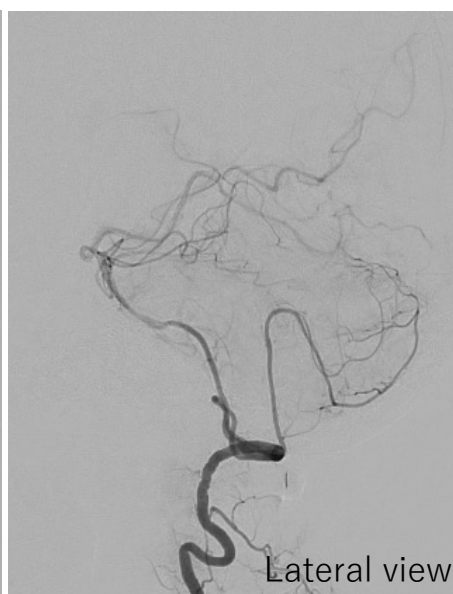
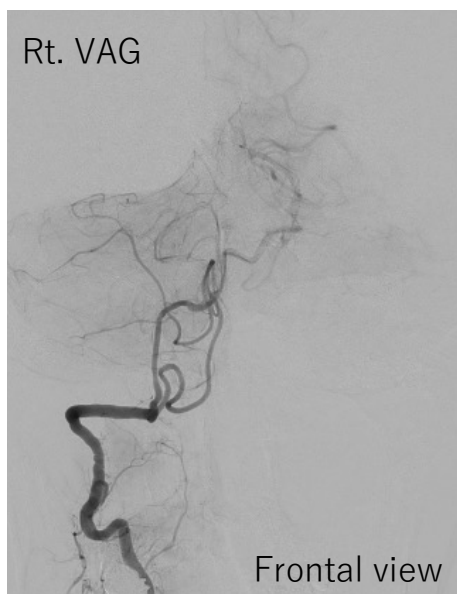
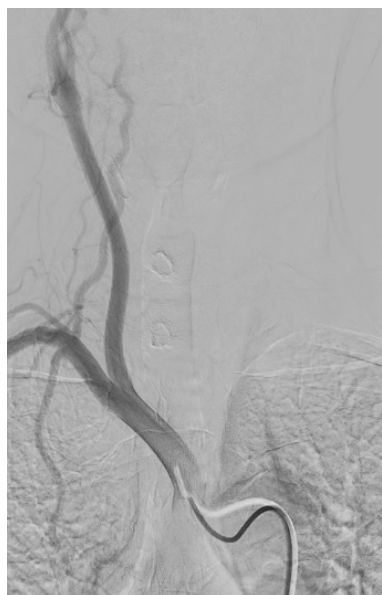CBCT (Lt. VAG)

coronal



Anastomosis (-) between  
aneurysm and ASA

Case KCGH-6	52歳、女性 52y, Female
病名 Diagnosis	左椎骨動脈解離性動脈瘤（部分血栓化） Lt. VA dissecting aneurysm (partially thrombosed)



Anastomosis (+) between  
rt. VA and ASA