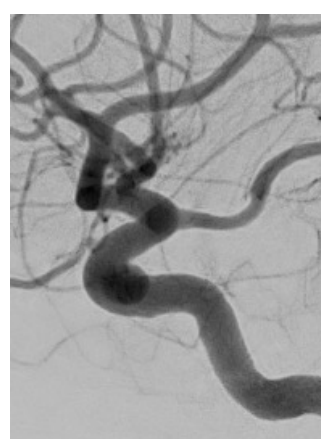
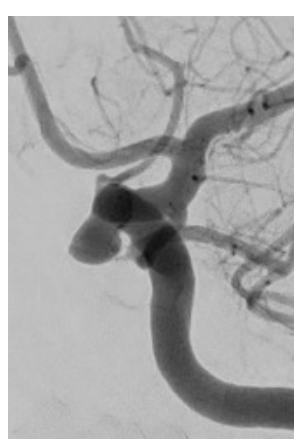
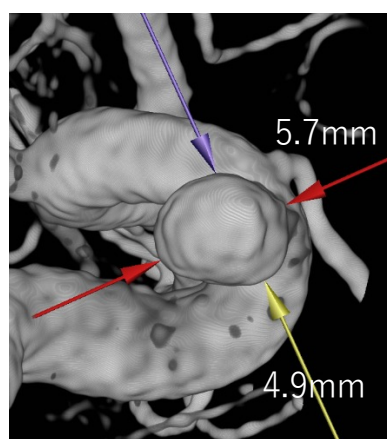
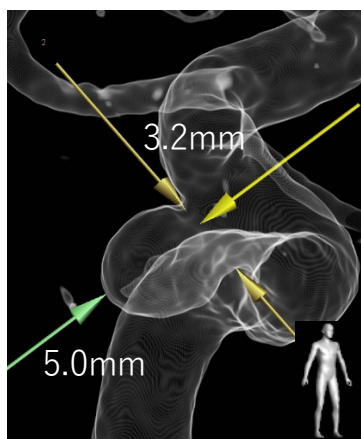
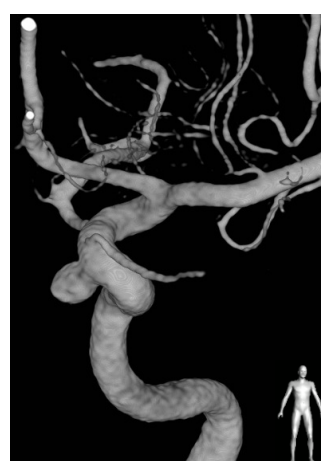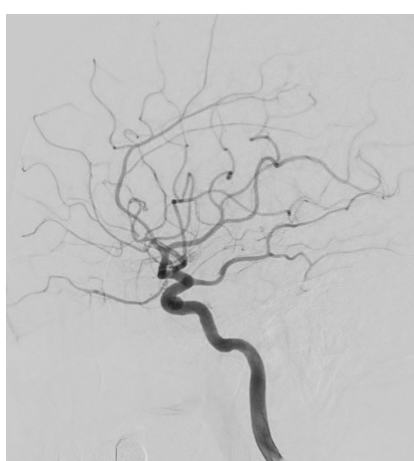

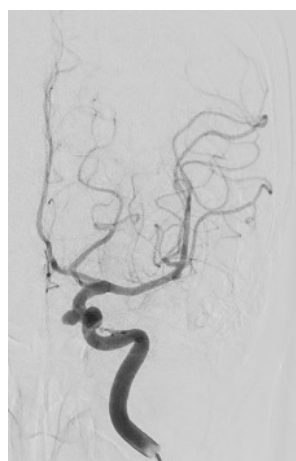
Case KCGH-2	65歳、女性 65y, Female
病名 Diagnosis	左内頸動脈瘤(C3) Left internal carotid artery (C3) aneurysm
現病歴 History	浮動性めまいの精査で偶発的に左内頸動脈の未破裂瘤が指摘された。 The patient was examined for dizziness. Imaging studies revealed an unruptured aneurysm of the left internal carotid artery incidentally.
既往歴 Past History	脂質異常症、右白内障、右半月板損傷 dyslipidemia, cataract in the right eye, right meniscus injury
内服薬 Medication	ピタバスタチンカルシウム、メチルコバラミン、ベニジピン、レボセチリジン pitavastatin calcium, methylcobalamin, benidipine, levocetirizine バイアスピリン100mg、クロピドグレル75mg (10日前から開始) Aspirin 100mg and Clopidogrel 75mg were started to be administered 10 days prior to the procedure.
家族歴 Family History	母：脳動脈瘤 mother : cerebral aneurysm



Neck : 3.19mm, Height : 4.98mm, Dome : 5.72mm*4.90mm

